

White Without Pressure (WWP)

Category(ies): Retina, Vitreous

Contributor: [Eric Chin, MD](#)

Photographer: Toni Venckus, CRA



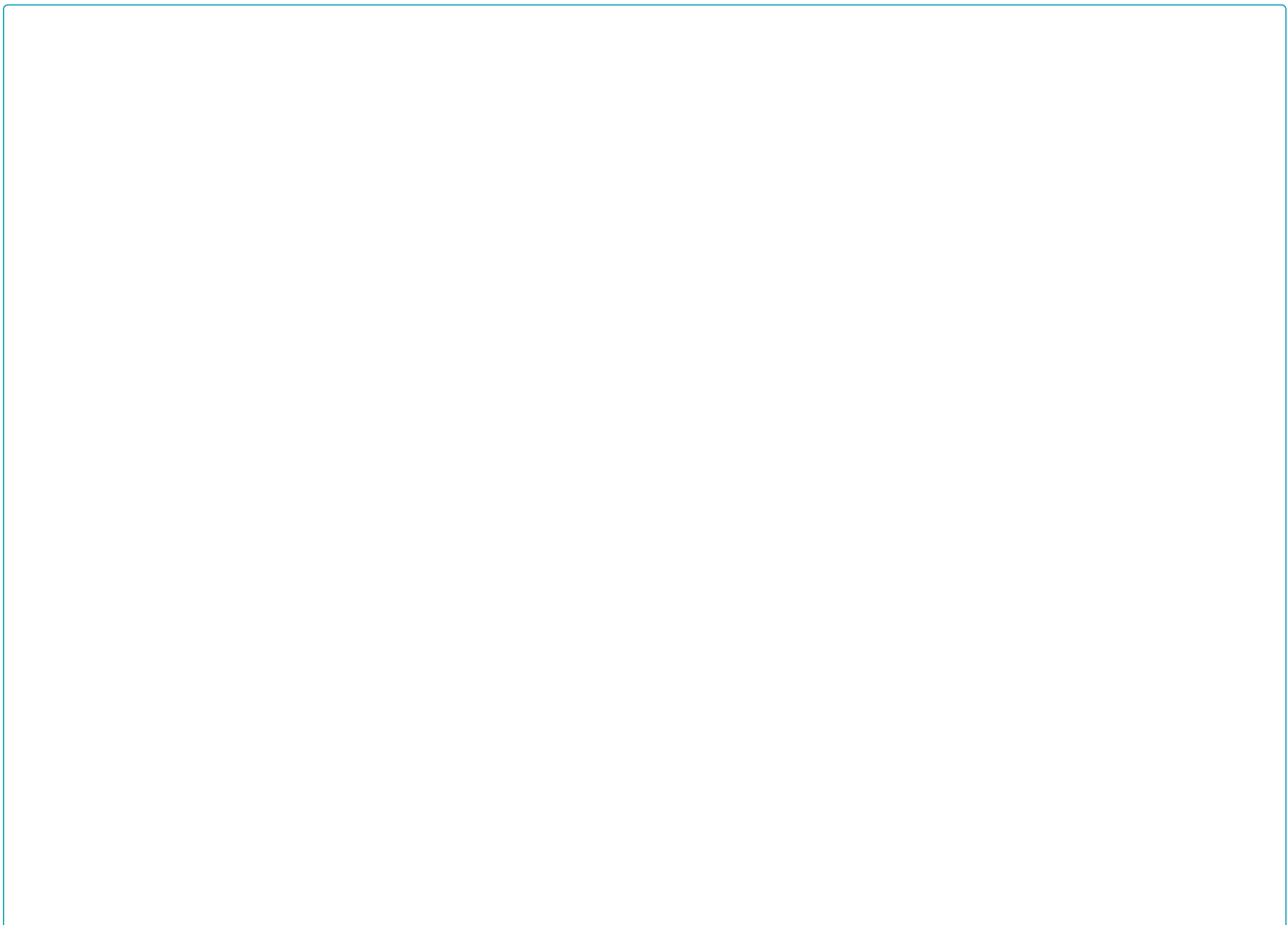
A 20-year-old male was seen in the Retina Clinic for the possibility of retinitis pigmentosa, both eyes. Unrelated to this, the peripheral exam showed relatively symmetric white patches of retina inferiorly and inferotemporally that were visible without scleral indentation. Scleral depressed exam revealed that the retina was attached, and that there was no other peripheral retinal pathology. The vision and remainder of the exam was otherwise unremarkable.

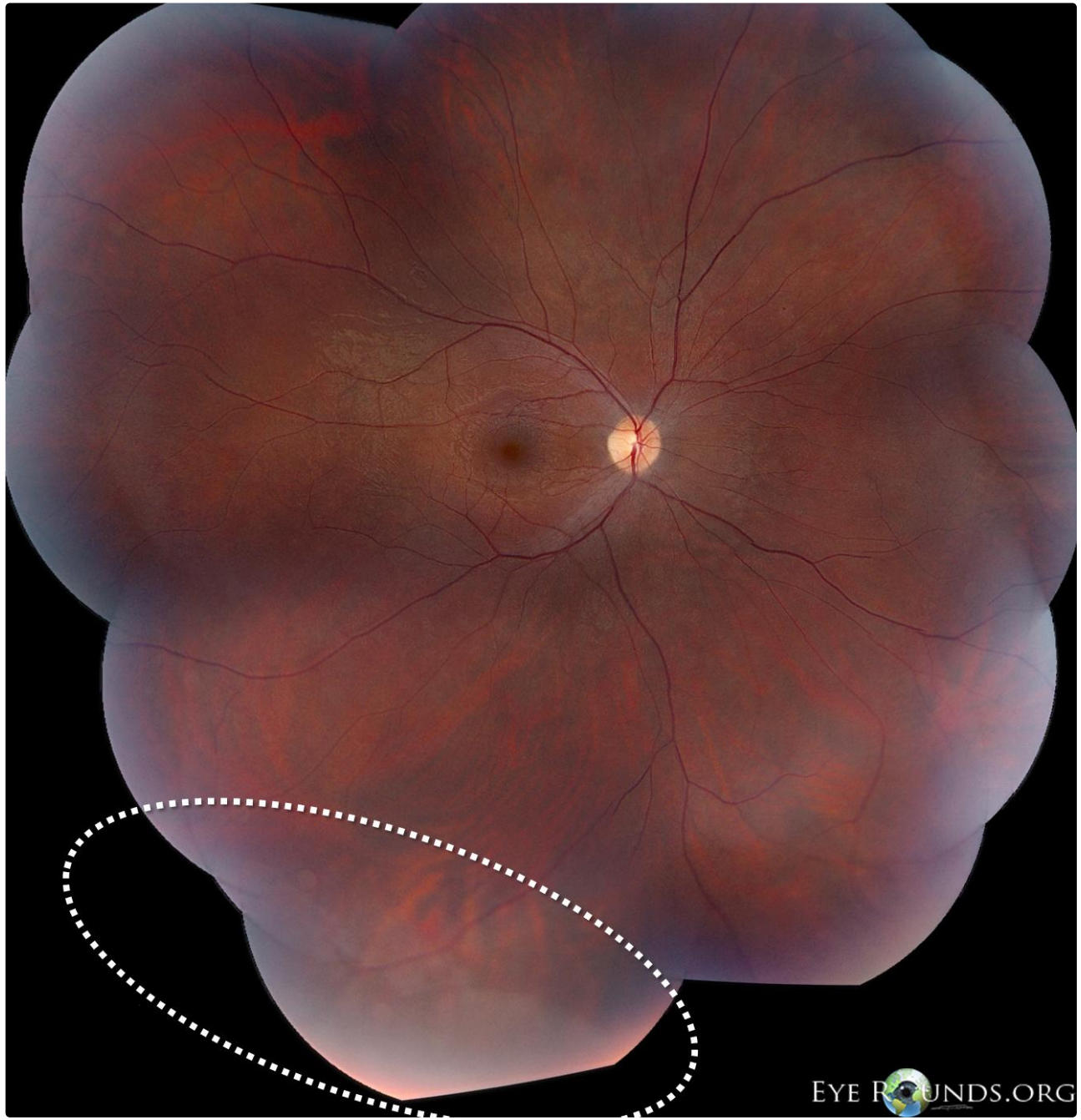
The exact cause of WWP is unknown. There has been controversy regarding its anatomical location, associated pathology, and its potential association with the development of retinal breaks.[1]

Clinically, a white appearance of the equator and/or peripheral retina seen without scleral indentation. Margins are often sharply demarcated from normal retina.

Frequently misdiagnosed as a retinal detachment or retinal schisis; however, scleral indentation reveals that the retina is apposed to the underlying RPE.

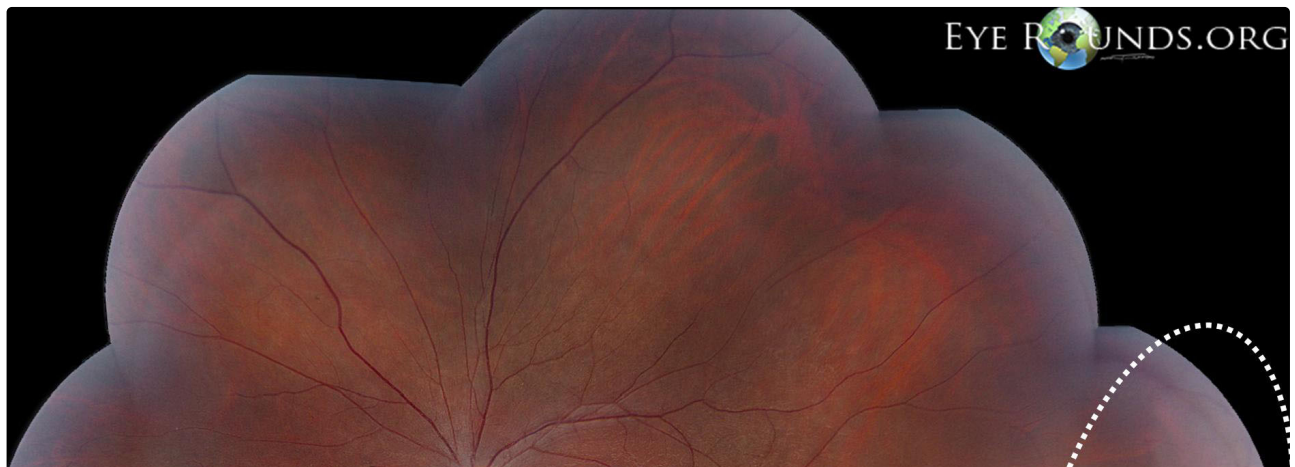
Reports show that OCT corresponds to a distinct hyper-reflectance of the outer retina, likely the elipsoid zone on SD-OCT.[2]



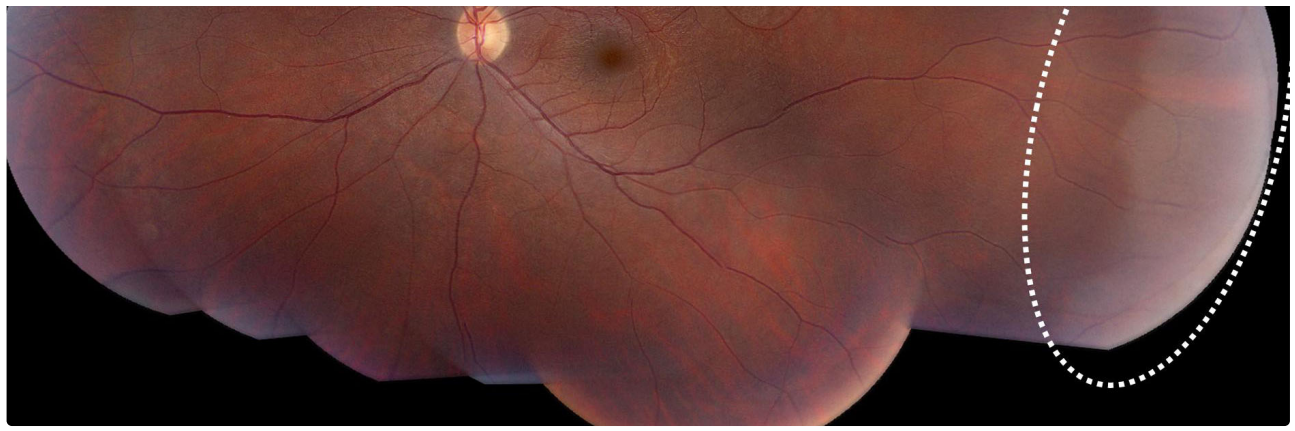


EYE ROUNDS.ORG

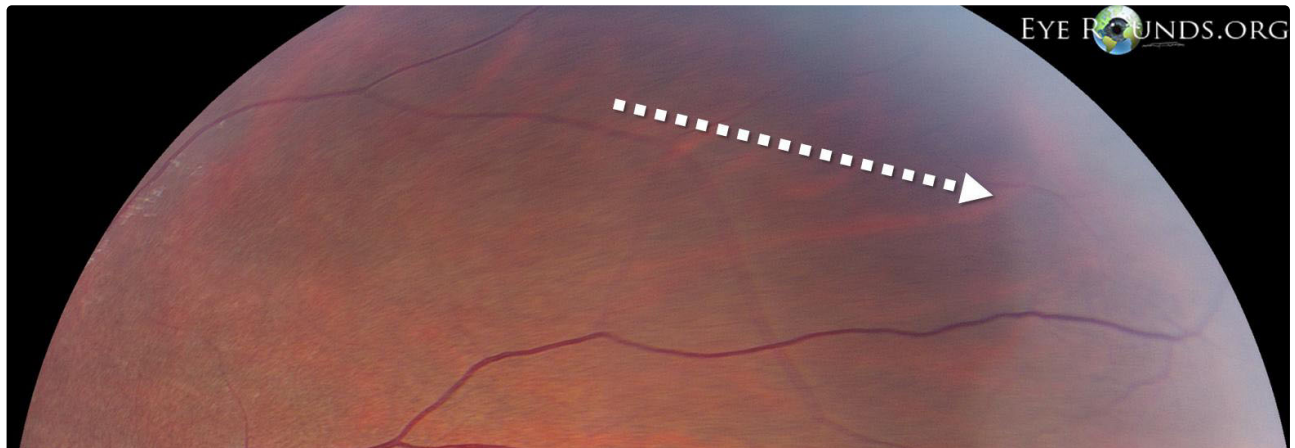
[Enlarge](#) [Download](#)

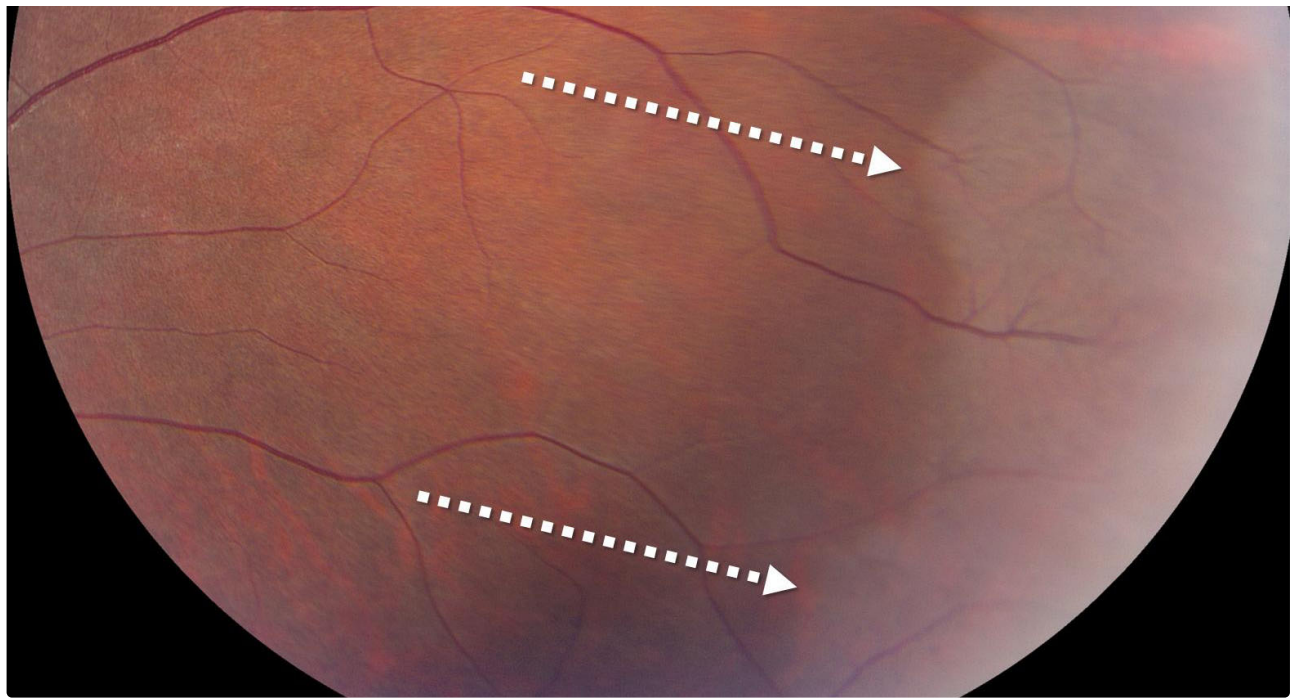


EYE ROUNDS.ORG



[Enlarge](#) [Download](#)

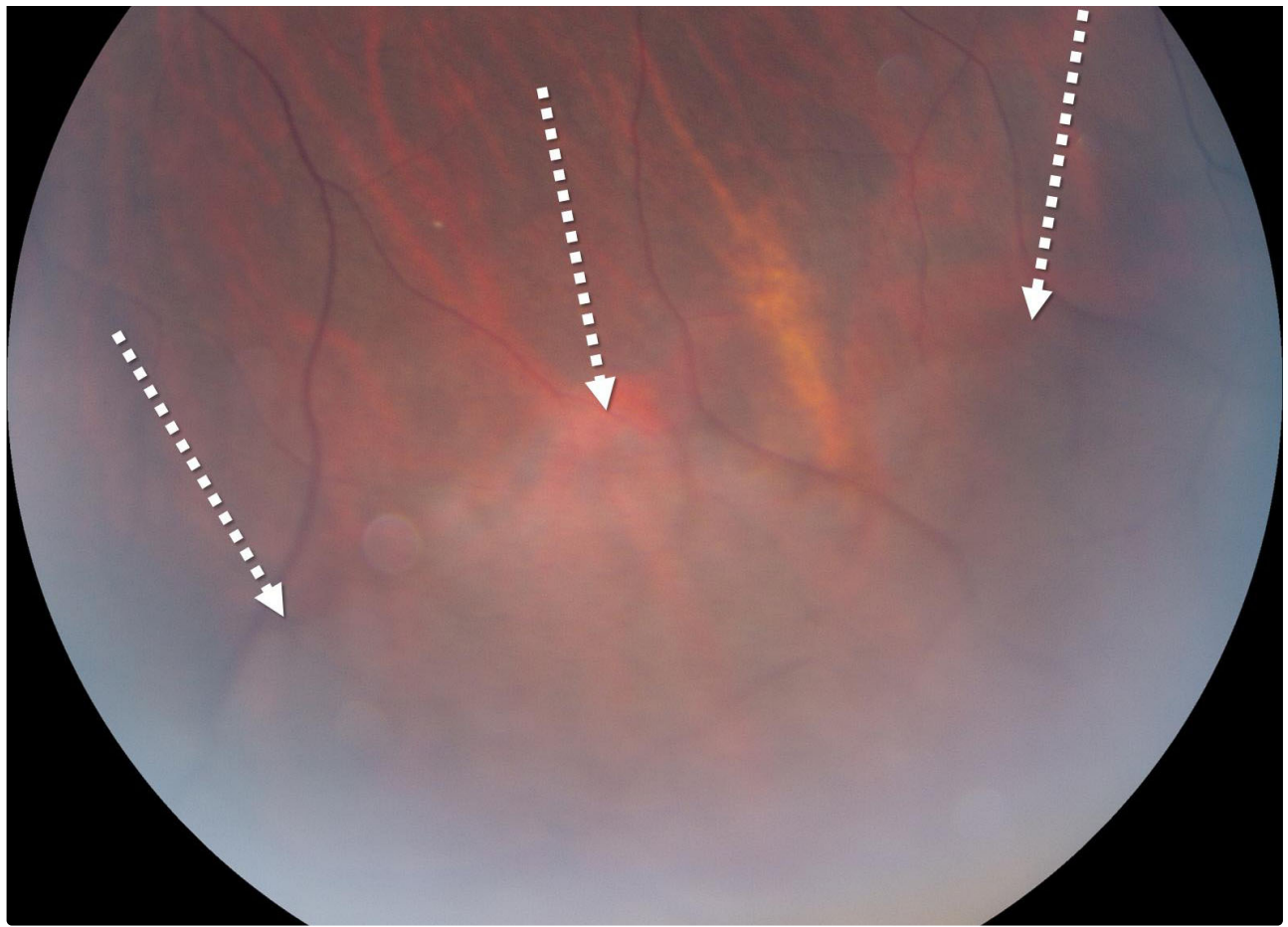




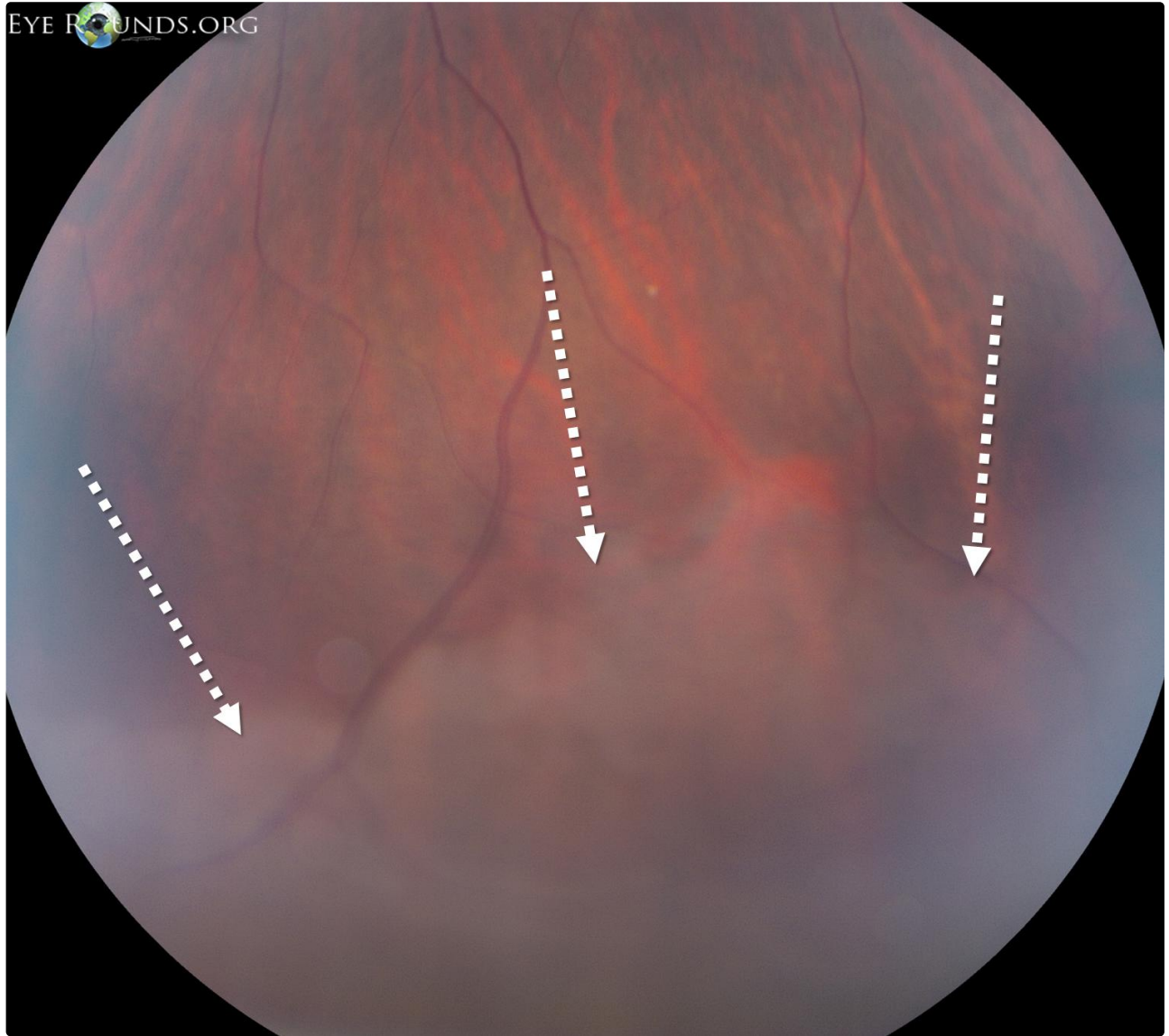
 Enlarge

 Download

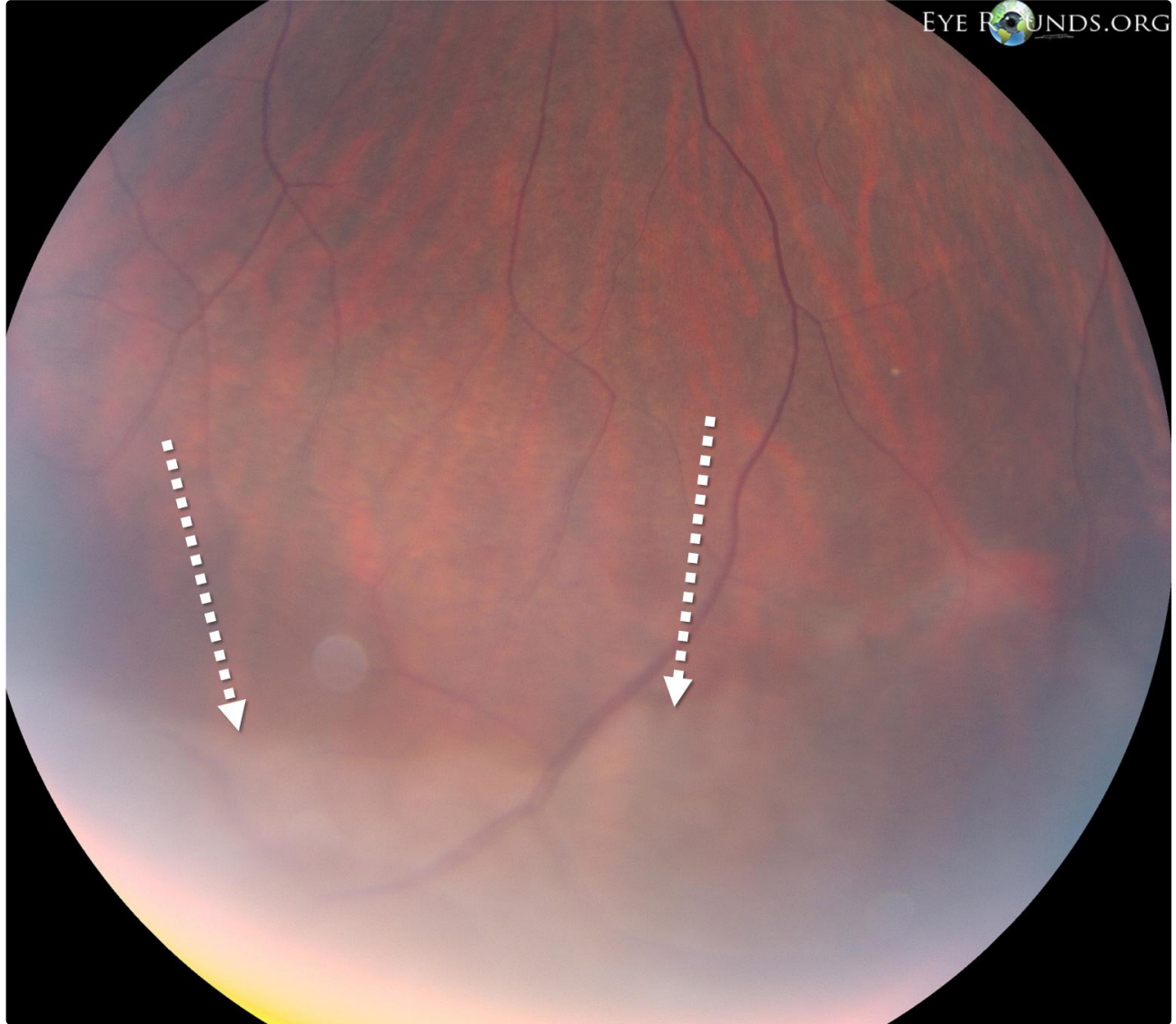




[Enlarge](#) [Download](#)

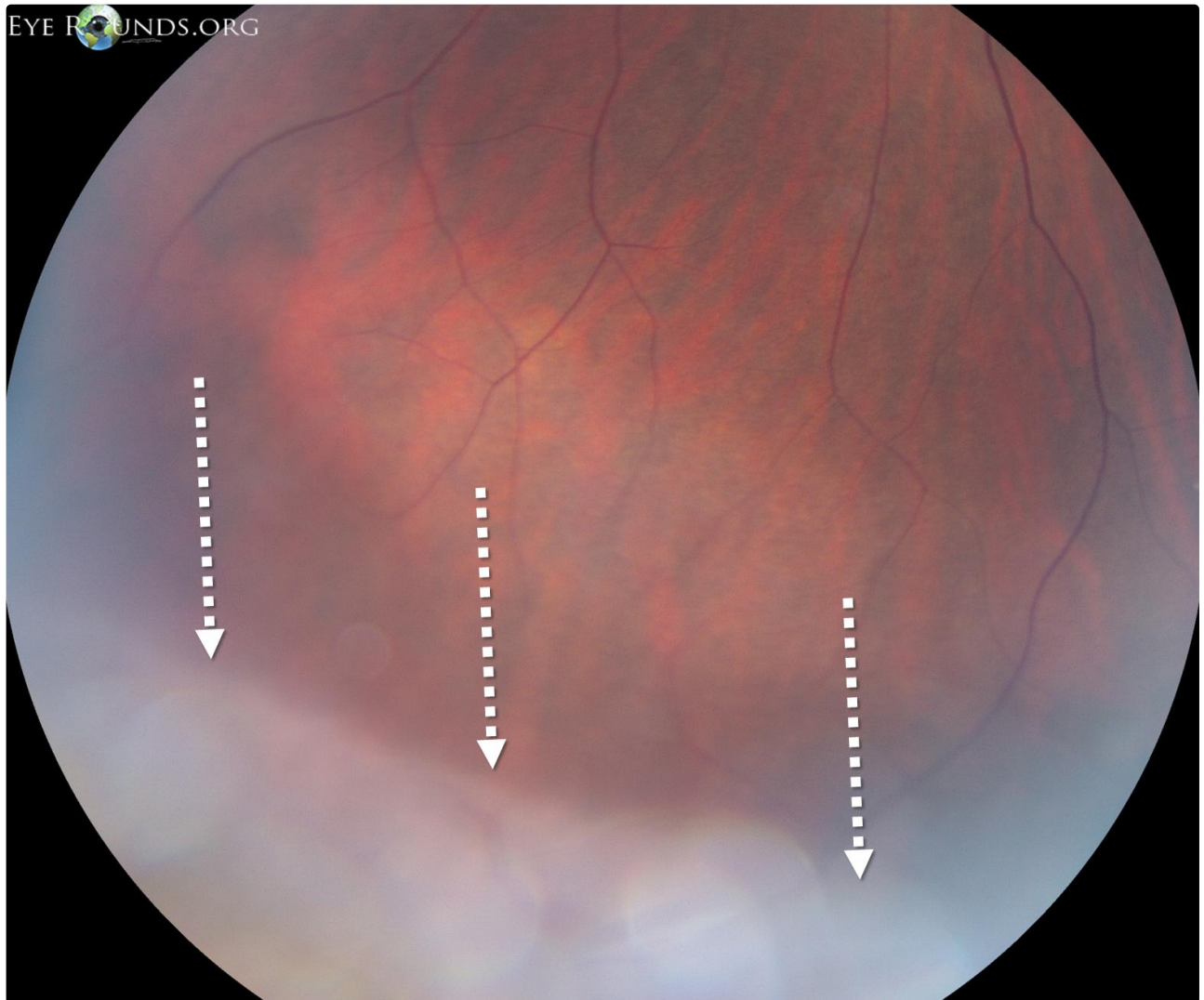


[Enlarge](#) [Download](#)



[Enlarge](#)

[Download](#)



 Enlarge

 Download

References:

1. Ryan SJ. Retina. Philadelphia, PA: Elsevier/Mosby; 2006.
2. Diaz RI, Sigler EJ, Randolph JC, Rafieetary MR, Calzada JI. [Spectral domain optical coherence tomography characteristics of white-without-pressure](#). Retina. 2014 May;34(5):1020-1. PubMed PMID: 24056529

Image Permissions:



Ophthalmic Atlas Images by [EyeRounds.org](https://www.eyerounds.org), [The University of Iowa](https://www.theuniversityofiowa.edu) are licensed under a [Creative Commons Attribution-NonCommercial-NoDerivs 3.0 Unported License](https://creativecommons.org/licenses/by-nc-nd/3.0/).

Address

University of Iowa
Roy J. and Lucille A. Carver College
of Medicine
Department of Ophthalmology and
Visual Sciences
200 Hawkins Drive
Iowa City, IA 52242

[Support Us](#)

Legal

Copyright © 2019 The University of
Iowa. All Rights Reserved
[Report an issue with this page](#)
[Web Privacy Policy](#) |
[Nondiscrimination Statement](#)

Related Links

[Cataract Surgery for Greenhorns](#)
[EyeTransillumination](#)
[Gonioscopy.org](#)
[Iowa Glaucoma Curriculum](#)
[Iowa Wet Lab](#)
[Patient Information](#)
[Stone Rounds](#)
[The Best Hits Bookshelf](#)

EyeRounds Social Media

Follow



Receive notification of new cases,
[sign up here](#)
[Contact Us](#)
[Submit a Suggestion](#)